

# SHOULDER INJURIES ATTRIBUTED TO RESISTANCE TRAINING: A BRIEF REVIEW

MOREY J. KOLBER, KRISTINA S. BEEKHUIZEN, MING-SHUN S. CHENG, AND MADELEINE A. HELLMAN

*Department of Physical Therapy, Nova Southeastern University, Fort Lauderdale, Florida*

## ABSTRACT

Kolber, MJ, Beekhuizen, KS, Cheng, M-SS, and Hellman, MA. Shoulder injuries attributed to resistance training: a brief review. *J Strength Cond Res* 24(6): 1696–1704, 2010—The popularity of resistance training (RT) is evident by the more than 45 million Americans who engage in strength training regularly. Although the health and fitness benefits ascribed to RT are generally agreed upon, participation is not without risk. Acute and chronic injuries attributed to RT have been cited in the epidemiological literature among both competitive and recreational participants. The shoulder complex in particular has been alluded to as one of the most prevalent regions of injury. The purpose of this manuscript is to present an overview of documented shoulder injuries among the RT population and where possible discern mechanisms of injury and risk factors. A literature search was conducted in the PUBMED, CINAHL, SPORTDiscus, and OVID databases to identify relevant articles for inclusion using combinations of key words: resistance training, shoulder, bodybuilding, weightlifting, shoulder injury, and shoulder disorder. The results of the review indicated that up to 36% of documented RT-related injuries and disorders occur at the shoulder complex. Trends that increased the likelihood of injury were identified and inclusive of intrinsic risk factors such as joint and muscle imbalances and extrinsic risk factors, namely, that of improper attention to exercise technique. A majority of the available research was retrospective in nature, consisting of surveys and descriptive epidemiological reports. A paucity of research was available to identify predictive variables leading to injury, suggesting the need for future prospective-based investigations.

**KEY WORDS** shoulder pain, resistance training injury, bodybuilding, weightlifting

## INTRODUCTION

The popularity of resistance training (RT) is reflected by the more than 45 million Americans who participate in some form of resistance training regularly (14). The Centers for Disease Control analyzed data from the National Health Interview Survey to determine the prevalence of strength training in the adult population from 1998 to 2004, and estimated that nearly 20% of adults aged 18–65 years participate in some form of resistance training 2 or more times a week (14). Resistance training has been advocated as a means of developing musculoskeletal strength for sports (6,24), rehabilitation of injuries (4,22), and for various health and fitness benefits (3,23,72). Although the health and performance benefits ascribed to RT are well documented, the pursuit of these benefits have not been without risk as a considerable number of RT-related injuries have been reported in the literature (27,35,36,41,61,62). The incidence of injuries attributed to RT has increased over the past decade, with 25–30% of participants reporting an injury severe enough to seek medical attention (59,79). Moreover, in the past few decades, the incidence of emergency department visits related to weightlifting has increased 35%, with about one-fourth of those injuries attributed to improper training (35,61).

The shoulder complex in particular accounts for a considerable proportion of injuries attributed to RT (11,18,26,27,30–32,41,57,61,62). Researchers have reported that up to 36% of injuries and disorders in the RT population occur at the shoulder complex (27,36,41,51). The susceptibility of the shoulder complex to injury is in part due to the considerable stress RT places on the shoulder joints, requiring a traditionally non-weight bearing joint to assume the role of a weight bearing joint during the course of repetitive lifting. Additionally, common RT exercises often place the shoulder in unfavorable positions such as end-range external rotation, while under heavy loads, predisposing the shoulder to both acute and chronic injuries. Moreover, upper extremity RT routines often emphasize large muscles that produce obvious gains in strength and hypertrophy, subsequently neglecting the smaller muscles responsible for stabilization. This combination of repetitive loading, unfavorable positioning and biased exercise selection creates joint and muscle imbalances, thus may place RT participants at-risk for injury (30,38,43). Although specific exercises are often cited as the

Address correspondence to Morey J. Kolber, kolber@nova.edu.

24(6)/1696–1704

*Journal of Strength and Conditioning Research*

© 2010 National Strength and Conditioning Association

cause of acute injury, the etiology of many chronic shoulder disorders in the RT population remains elusive. The ability of clinicians and strength and conditioning professionals to recognize “at-risk” training patterns requires an awareness of documented injury trends and risk factors.

The purpose of this manuscript is to present an overview of the literature pertaining to shoulder injuries in the RT population and to elucidate the etiological risk factors hypothesized to be associated with the more common injuries. Where possible efforts were made to delineate the specific population studied (recreational vs. competitive); however, a majority of injuries discussed in the literature were common to all styles of RT; thus, “resistance training” as referred to in this article pertains to all levels of participation. For the purpose of this review, the term “shoulder injury” refers to any acute or chronic shoulder disorder that manifests as pain or interferes with the performance of RT participation.

### Shoulder Injuries

Epidemiological reports cite the shoulder complex as a primary region of injury with prevalence rates ranging from 22% to 36% (27,36,41). Keogh et al. (36) investigated injury patterns using a retrospectively survey of competitive Oceania weightlifters ( $n = 101$ ). In their study, the shoulder complex comprised 36% of all reported injuries and was the region most often affected. Goertzen et al. (27) investigated both period and point prevalence of injuries in subjects ( $n = 358$ ) who participated in RT and reported the shoulder complex to be the most prevalent region of injury at 34%. Konig and Biener (41) surveyed the athletic population on past injuries because of weight lifting and found that of the reported injuries 22% were at the shoulder complex. A survey of 60 recreational RT participants revealed that 60% had reported shoulder pain during the course of RT in the past year, whereas 28% had pain during RT in the past 3 days (38).

In addition to prevalence based investigations, numerous case reports and descriptive studies have documented RT-related shoulder injuries (1,5,10,12,18–21,26,30,32,43,49,66,67). Injuries documented in the literature comprised both acute trauma and nontraumatic musculoskeletal disorders and consisted of soft tissue injuries, acromioclavicular disorders, instability, dislocations, and peripheral nerve injuries. The reported injuries were classified in this review according to the type of injury and associated risk factors.

### Soft Tissue injuries

Soft tissue injuries reported among the RT population primarily include the rotator cuff (primarily supraspinatus), biceps, and pectoralis major musculature (5,13,18,19,27,41,51,62,75,76,79). In a survey of 121 weightlifters who had reported being injured during the course of RT, 27% reported having a past history of shoulder pain during lifting, which resulted in limited ability to exercise for up to 7 days (41). The region of pain most often identified included the long head of the bicep (at the shoulder origin) and supraspinatus musculature. Injury patterns in a

sample of 12 amateur lifters referred for a nuclear bone scan examination were investigated (76). The sample consisted of subjects who participated in RT primarily as an adjunctive method to increase strength for sporting activities. Results from the investigation revealed that most injuries occurred at the shoulder region and that primary areas of involvement included the long head bicep and rotator cuff tendons. Cope et al. (18) reported 3 cases of long head bicep ruptures as a direct result of RT.


Injuries to the pectoralis major often manifest as acute trauma. The pectoralis major musculature is a major source of power during upper extremity exercises and is often a region of desired hypertrophy leading to concentrated training efforts directed to this muscle. Researchers have documented multiple case reports of pectoral ruptures attributed to RT (5,13,75). Bak et al. (5) conducted a meta-analysis of 112 case reports of pectoralis major ruptures. From the results of the investigation, it was found that pectoralis major ruptures most often occur in the abducted-externally rotated high-five position (Figures 1A–C), and weightlifting was responsible for 54 of the 112 cases reviewed. Furthermore, 29 of the 112 cases occurred specifically as a result of bench pressing (5). An investigation of pectoralis major ruptures resulting from bench press indicated that the shoulder is most susceptible to rupture during the lowering-eccentric phase (78). In addition to the bench press, pectoralis major ruptures have been reported as a result of other exercises such as bar dips and chest flies (5,13).

### Acromioclavicular Joint Injuries

The acromioclavicular joint is subject to increased stress during the course of upper extremity RT predisposing this joint to a condition referred to as osteolysis of the distal clavicle (12,31,62,67,68,71,76). Osteolysis of the distal clavicle also known as “weightlifter’s shoulder” is characterized by a widening of the acromioclavicular joint, subchondral stress fractures, and bone lysis at the distal clavicle where it forms the acromioclavicular joint. (12,67,68,79). This condition specifically has been associated with the bench press exercise as a result of repeated microtrauma at the acromioclavicular joint during the lowering phase of the exercise when the arm is extended posterior to the trunk (31). An investigation of 46 athletes diagnosed with distal clavicle osteolysis revealed that 45 of the 46 athletes participated in RT exercises (12). Other investigators reported a 27% prevalence of distal clavicle osteolysis in (67). Yu and Habib (79) presented a review of the literature regarding common injuries related to RT that were identified through magnetic resonance imaging and reported a 28% prevalence of distal clavicle osteolysis in weightlifters.

### Instability and Dislocations

Anterior shoulder instability at the glenohumeral joint has been documented among the RT population (19,21,30–32,49,57). Unfavorable positions assumed during common exercises such as bench press, behind the neck pull-downs, military presses, and chest flies may predispose the RT population to anterior shoulder instability (30,62). Shoulder



**Figure 1.** A) The high-five position. Position places the arm in end-range external rotation with abduction. B) The seated chest fly machine requiring the high-five position. C) The behind the neck military press requiring the high-five position.

positions requiring the humerus to be extended posterior to the trunk or that require the high-five position place stress on the anterior shoulder tissues, thus may excessively increase mobility and over time lead to decreased stability. Gross et al. (30) examined 20 subjects that were experiencing shoulder pain during RT. In the investigation, all of the subjects reported pain when assuming the simultaneous abduction-external rotation “high-five” position (Figures 1A–C), and during RT activities such as chest flies and bench press. Common clinical findings among the subjects included anterior shoulder instability purported to be a result of performing exercises that required the arm to be extended posterior to the trunk or the high-five position (30). Reeves et al. (61,62) reviewed both acute and chronic injuries resulting from RT. The authors suggested that extension of the shoulders past the trunk during bench press or chest flies contribute to anterior glenohumeral instability. Additionally, the authors suggested an association between behind the neck latissimus pull-downs, and both rotator cuff injuries and anterior shoulder instability. Yu and Habib reported an increased frequency of anterior instability and subluxation associated with the bench press exercise as a result of shoulder positioning (79).

Reports of acute anterior shoulder dislocations associated with RT have appeared in the literature (19,21,31,32,49). Although rare among the general and athletic population, reports of bilateral anterior glenohumeral dislocations occurring from performance of the bench press exercise have been documented (19,32,49). Esenkaya et al. (21) reported a bilateral anterior glenohumeral dislocation in an individual performing seated behind the neck military presses, whereas another case report (49) identified a bilateral anterior glenohumeral dislocation during a benching pull-over exercise. The shoulder is often dislocated in the high-five position (referred to as the apprehension position in the clinical setting); thus, exercises requiring the high-five position while under heavy loads may predispose the shoulder to dislocations.

#### Peripheral Nerve Injuries

Peripheral nerve injuries may occur from RT as a result of both chronic and acute mechanisms. A variety of causative factors have been suspected, including improper technique, overtraining, direct trauma, stretch injuries from end-range positions, and muscle hypertrophy (46). Although the incidence of peripheral nerve injuries is rare, accounting for less than 8% of RT injuries (46), specific nerves are more vulnerable to stretch or compression neuropathy as a result of their location.

Suprascapular neuropathy has been reported in multiple case reports among lifters, exceeding the general population (1,46,81). Reports suggest that the suprascapular nerve is affected by compression during exercises such as the military press (46,63). Musculocutaneous neuropathy has been reported among the RT population as a result of

coracobrachialis and brachialis musculature hypertrophy (9,10,33,46). Braddom and Wolf (10) reported 3 cases of musculocutaneous neuropathy resulting from heavy resistance training and suggested intramuscular compression as the mechanism of injury. Long thoracic and medial pectoral neuropathy have been described in the RT population, and hypothesized to result from nerve traction and intramuscular hypertrophy, respectively. Specific exercises such as the military press and latissimus pull down have been implicated as causative factors responsible for long thoracic neuropathy. Lifting weights overhead is hypothesized to create upward traction on the nerve, thus causing a stretch induced neuropathy (29,46,58,69,80). Medial pectoral neuropathy has been reported in the RT population primarily as a result of pectoral muscular hypertrophy causing intramuscular entrapment (9,55,66). Lastly, the lower trunk of the brachial plexus may be compressed from muscular tightness or hypertrophy of the anterior scalene, upper trapezius, or pectoralis minor musculature (46,50). RT participants in particular, as a result of their typical body habitus and exercise, focus may develop such hypertrophy and tightness that may lead to neuropathic changes. It should be noted however that the overall the incidence is rare when compared with other mechanisms of RT-induced injuries.

**Risk Factors**

Variables implicated in the etiology of both acute and chronic shoulder injuries were identified and classified as either intrinsic or extrinsic risk factors.

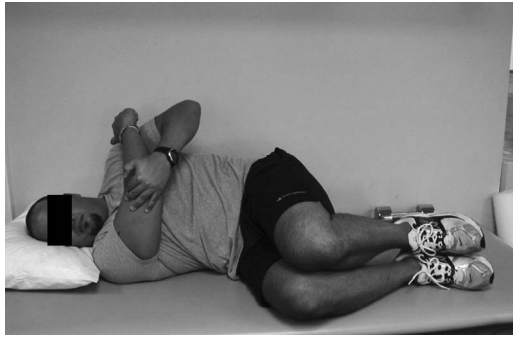
Intrinsic risk factors such as aberrant joint and muscle characteristics that develop as a result of RT are hypothesized to increase injury risk. Aberrant risk factors found in the RT population generally included muscle strength imbalances, anterior shoulder instability, and a loss of mobility as listed in Table 1. An appropriate balance of agonist and antagonist muscle strength is necessary to provide sufficient active stability for maintenance of normal shoulder kinematics. Exercise selection that emphasizes large muscle groups may create an imbalance of the internal vs. external rotator cuff musculature, rotator cuff–deltoid force couple, and scapular musculature. Muscle strength imbalances interfere with normal shoulder function and have been associated with shoulder injury in numerous investigations (15–17,45,48,60,70). Resistance training routines often focus on large muscle groups such as the pectoralis major, upper trapezius, and deltoids, while neglecting muscles responsible for shoulder stabilization such as the rotator cuff and scapular musculature, thus predisposing participants to injury (6,30,38,39). Researchers have reported weakness of the stabilizing rotator cuff and scapular musculature among the RT population (6,38,39). Specifically, when comparing the shoulder external rotators to internal rotators, deltoid to external rotators and upper to lower trapezius muscle imbalances have been identified in the RT population exceeding that of the general population (38,39).

Shoulder mobility imbalances in individuals who participate in overhead sports have been described in the literature (8,53). Overhead motions typically required during RT position the arm into the abducted and externally rotated high-five position, which has been associated with shoulder

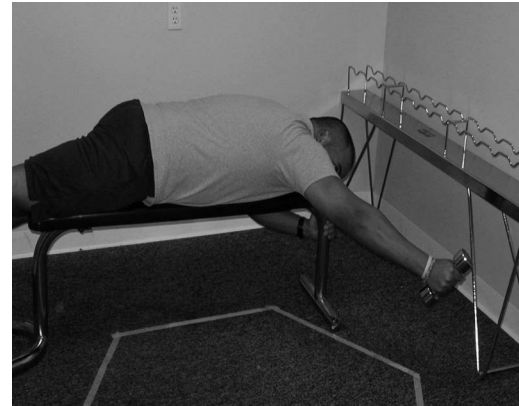**TABLE 1.** Shoulder joint and muscle imbalances associated with RT.

Author	Type of investigation	Participation level	Sample size	Findings
Barlow et al (6)	Descriptive investigation with control group comparison	Bodybuilders	29	1. Limited internal rotation mobility 2. Lower trapezius strength was not significantly greater in bodybuilders when compared to controls
Gross et al (30)	Case series	Symptomatic weightlifters described as athletes	20	1. Occult anterior shoulder instability
Kolber (38)	Descriptive investigation with control group comparison	Recreational RT participants	60	1. Limited internal rotation mobility 2. Excessive external rotation mobility 3. Posterior shoulder tightness 4. Relative weakness of: –External rotators compared to internal rotators –External rotators compared to abductors –Lower trapezius compared to upper trapezius 5. Occult anterior shoulder instability

\*RT = resistance training.



**Figure 2.** Cross arm adduction stretch designed to increase posterior shoulder flexibility. Individuals lie on side to be stretched and rolls torso back about 45° until they are weight bearing on the scapula. Once in position, the arm is pulled across the body at the level of the pectorals until a stretch is felt in the posterior shoulder. Stretch is held for 30 seconds and repeated 3 times.



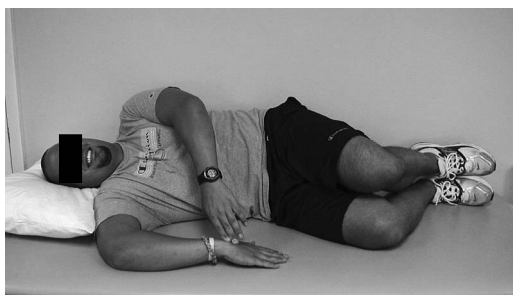**Figure 4.** Prone arm abduction in the scapular plane. Individuals lie on their stomach (prone) and raise arm up to the diagonal plane while maintaining a thumb up position.

dysfunction (2,22,25,30,31,53,54,57,62,82). Upper extremity RT places the shoulder in the high-five position (required during exercises such as the behind the neck military press and pull-downs) under heavy loads creating anterior capsular overload leading to anterior instability and impingement (30,31,53,54,57). Gross et al. (30) identified anterior shoulder instability among RT participants and postulated that the high-five position frequently assumed during exercise was a contributing factor.

A loss of shoulder internal rotation and posterior capsule tightness have been implicated as etiological risk factors for shoulder dysfunction (2,34,37,44,47,56,73,74,77). Resistance training often requires end-range external rotation during the more common exercises thus the relative infrequency of end-range internal rotation during RT results in a relative

loss of internal rotation and posterior shoulder tightness (38,39). Investigators have identified a statistically significant limitation of internal rotation in weightlifters when compared with a control group (6,38,39) thus suggesting RT as a risk factor for reduced shoulder mobility.

Shoulder injuries in the RT population resulting from improper shoulder positioning during common exercises have been well documented in the literature (7,27,28,30,32,49,51,57,64,65,75,79). Gross et al. (30) investigated anterior



**Figure 3.** Internal rotation sleeper stretch. Individuals lie on side to be stretched and rolls torso back about 45°s until they are weight bearing on the scapula. Their arm is placed at shoulder level and elbow flexed 90°. Once in position, the arm with assistance of the opposite arm is brought to the table or mat while maintaining a flexed elbow. Stretch is held for 30 seconds and repeated 3 times.



**Figure 5.** Standing resisted external rotator strengthening. Individual may use cables or a resistance band and brings arm from waist out to side.



**Figure 6.** Bench press modification using a towel roll to limit the terminal lowering phase end-range.

instability in a sample of 20 RT participants. In this investigation, exercises such as wide grip bench press, incline bench press, incline chest flies, supine chest flies, behind the neck pull-downs and military presses were identified as pain producing exercises. Resistance training injury trends from 1978 to 1998 were reported in a retrospective review and revealed a 35% increase in injury rates over the 20-year period with a high proportion of injuries resulting from improper use of free weights exceeding that of machines (35). The author estimated about 25% of the injuries to have occurred from the misuse or abuse of RT equipment. Moreover, a gender comparison revealed a higher injury rate among men than women as men comprised 80.5% of the documented injuries (35). Risser (65) reviewed the types, incidence, and causes of RT injuries among children and adolescents. In this review, the author reported multiple causes of injuries; however, of note was that many injuries were attributed to exercises such as squats, dead lifts, bench press, incline bench press, and overhead presses. The author reported an increased injury risk when appropriate warm-up, proper exercise technique, and pain-free resistance were not adhered to. Haupt (31) discussed common upper extremity injuries associated with RT and postulated that exercise selection including bench press, parallel dips, behind the neck military press, incline bench press, behind the neck pull-downs, back squat exercise, dumbbell chest flies, and bicep curls may increase injury risk to the shoulder.

## DISCUSSION

Resistance training programs are often performance based as opposed to prevention based, thus predisposing both the competitive and recreational participant to injury. Improper attention to exercise technique, biased exercise selection,



**Figure 7.** Modification of the dumbbell shoulder press exercise. A) Traditional form requiring the end-range high-five position, B) Modification to avoid terminal high-five position.

unfavorable shoulder positioning required of the more common exercises along with the repetitive nature of lifting heavy weight until failure, increases the likelihood of injury. Although the specific nature of many injuries was not identified in the literature, evidence was available to suggest that acute and chronic injuries may be precipitated by certain training patterns. Additionally, trends for specific types of injuries resulting from RT were identified that may serve the basis for preventative efforts.

The most common sites of soft tissue injury included the biceps, rotator cuff and pectoralis major musculature. Of those cases with a known etiology the bench press was often implicated as a causative factor along with exercises that required participants to assume the high-five position. Joint-

related disorders included anterior shoulder instability that was often postulated to be the result of the high-five position that is assumed during exercises such as behind the neck military press and latissimus pull-downs. Biomechanically, the high-five position may lead to overstretching of the anterior shoulder tissue leading to excessive anterior translation and thus instability.

Osteolysis of the distal clavicle often referred to as weight-lifters shoulder because of the increased incidence among the RT population was often attributed to the bench press. Peripheral nerve injuries, albeit rare were often precipitated by a stretch type mechanism or from compression because of muscular hypertrophy. Because of the body habitus of the RT population, hypertrophy of the pectorals and brachialis musculature was responsible for a substantial portion of compressive neuropathies. Stretch neuropathies were often a result of positioning the shoulder at end ranges.

In regard to exercise selection, performance of the bench press was often implicated in shoulder injuries including osteolysis, soft tissue strains and tears, anterior instability, and dislocations. The lowering-eccentric phase of the bench press was postulated to be responsible for many of the injuries particularly when the arm was lowered below the torso. Additionally, exercises requiring the high-five position were associated with anterior shoulder instability, shoulder pain, dislocations and pectoralis major tears. From a perspective of shoulder positioning, most injuries with a known positional mechanism cite either the high-five position assumed during shoulder presses, behind the neck military presses, and behind the neck latissimus pull-downs, or the lowering phase of the bench press when the arms are extended posterior to the torso.

Lastly, RT routines that focus on large muscle groups while neglecting muscles responsible for shoulder stabilization such as the rotator cuff and scapular musculature (6,30,38,39) may predispose participants to shoulder strength imbalances. Specifically when comparing the shoulder external rotators to internal rotators, deltoid to external rotators and upper to lower trapezius muscle imbalances have been identified in the RT population exceeding that of the general population (38,39). The specific strength imbalances have been implicated in the etiology of shoulder disorders such as impingement syndrome and scapular dyskinesis in the general and athletic populations.

Research has identified training variables to improve strength, performance, and muscle hypertrophy; however, the etiological risk factors and undesired strength and mobility adaptations prospectively leading to shoulder injury and dysfunction have not been thoroughly investigated. A majority of the documented shoulder injuries identified in the literature were from retrospective surveys and descriptive epidemiological reports; thus, it is difficult to posit with certainty the precise etiological mechanisms of injury in nontraumatic cases. Additionally, many of the surveys use an athletic population, so it may be difficult to ascertain the true etiology of these injuries (sport vs. RT). Some of the common

myths such as low repetitions or heavy weights being responsible for injuries were not supported in this review. Moreover, there was no evidence that individuals who lifted lighter weights and higher reps were less at-risk than the individual performing 1 repetition maximum or power lifting. Lastly, RT cannot be grouped as one modality. Although several surveys delineated the specific level of participation and exercise selection many did not. One must exercise caution when interpreting injury surveys because there are various levels of participation and not all training programs and designs are of the same intensity and format despite being labeled as RT.

Future research is necessary to gather evidence-based guidelines to prevent and alleviate risk factors. With an understanding of appropriate modifications and alternatives, the goals of improved conditioning and performance may be achieved without the associated risks.

### PRACTICAL APPLICATIONS

Given the propensity for shoulder injury in the RT population, it is suggested that known risk factors be addressed a priori as a means of preventing injury. An awareness of risk factors and injury trends associated with RT may serve the basis for evidence-based injury prevention efforts and exercise modifications.

Exercises that address aberrant joint and muscle characteristics such as weakness of the rotator cuff and scapular musculature along with mobility restrictions may be incorporated into current training routines. Incorporating select flexibility exercises for the posterior shoulder tissue (Figures 2 and 3) may improve posterior shoulder restrictions and internal rotation mobility (40,42,52). Additionally, an improvement of posterior shoulder flexibility may provide for mobility balance in the abducted-externally rotated "high-five" position to avoid excessive anterior translation. Strengthening of the rotator cuff and scapular musculature into RT routines will theoretically (a) balance strength ratios to sufficient levels required for normal shoulder kinematics, (b) provide stability in the abducted-externally rotated "high-five" position to avoid excessive anterior translation, and (c) improve strength of the humeral head depressors to avoid impingement with overhead exercises common to RT. Select exercises including the prone scapular plane abduction exercise and resisted external rotation (Figures 4 and 5) have been found efficacious for activating both the scapular and rotator cuff musculature, thus may be of benefit to mitigate muscle imbalances derived from scapular and rotator cuff weakness.

Lastly, recognizing the association of improper exercise selection (extrinsic risk) and shoulder dysfunction may reverse or prevent patterns of injury. Limiting the end-range positioning on the bench press through the use of a towel roll or barbell pad (Figure 6) may mitigate risk from the terminal lowering phase. Moreover, avoiding the end-range "high-five" position through exercise modifications (Figures 7A, B) may prevent the development of anterior shoulder instability



and pain. This may additionally be achieved through the selection of exercises that require bringing the bar to the front of the torso (latissimus pull-downs or barbell presses to the front) instead of behind the neck.

The professions involved in both the prescription of exercise, and the evaluation and treatment of musculoskeletal disorders must develop guidelines that optimize safety, reduce injury risk, and prevent musculoskeletal dysfunction in the RT population. Injury risk may be mitigated through changes in exercise prescription and technique; however, investigations are needed to ensure performance is not compromised and to determine the true longitudinal benefit from such modification.

The key points are as follows: (a) Incorporating exercises to strengthen the lower trapezius and external rotators may serve to mitigate common strength imbalances associated with RT. (b) Flexibility exercises designed to increase internal rotation and improve posterior shoulder flexibility are recommended to avoid shoulder disorders and provide balanced joint mobility. (c) Avoiding the true “high-five” position (Figure 1A) with basic technique modifications may serve useful in preventing more common RT-induced shoulder disorders.

## REFERENCES

1. Agre, JC, Ash, N, Cameron, MC, and House, J. Suprascapular neuropathy after intensive progressive resistive exercise: case report. *Arch Phys Med Rehabil* 68: 236–238, 1987.
2. Altchek, DW and Dines, DM. The surgical treatment of anterior instability: Selective capsular repair. *Oper Tech Sports Med* 1: 285–292, 1993.
3. American College of Sports Medicine. Position stand on the recommended quantity and quality of exercise for developing and maintaining cardiorespiratory and muscular fitness in healthy adults. *Med Sci Sports Exerc* 22: 265–274, 1990.
4. American Physical Therapy Association. *Guide to Physical Therapist Practice*. Alexandria, VA: American Physical Therapy Association, 1999.
5. Bak, K, Cameron, EA, and Henderson, IJ. Rupture of the pectoralis major: A meta-analysis of 112 cases. *Knee Surg Sports Traumatol Arthrosc* 8: 113–119, 2000.
6. Barlow, JC, Benjamin, BW, Birt, P, and Hughes, CJ. Shoulder strength and range-of-motion characteristics in bodybuilders. *J Strength Cond Res* 16: 367–372, 2002.
7. Basford, JR. Weightlifting, resistance training and injuries. *Orthopedics* 8: 1051–1056, 1985.
8. Bigliani, LU, Codd, TP, Connor, PM, Levine, WN, Littlefield, MA, and Hershon, SJ. Shoulder motion and laxity in the professional baseball player. *Am J Sports Med* 25: 609–613, 1997.
9. Bird, SJ and Brown, MJ. Acute focal neuropathy in male weight lifters. *Muscle Nerve* 19: 897–899, 1996.
10. Braddom, RL and Wolf, C. Musculocutaneous nerve injury after heavy exercise. *Arch Phys Med Rehabil* 59: 290–293, 1978.
11. Budoff, JE and Gordon, L. Surgical repair of a traumatic latissimus dorsi avulsion: A case report. *Am J Orthop* 29: 638–639, 2000.
12. Cahill, BR. Osteolysis of the distal part of the clavicle in male athletes. *J Bone Joint Surg Am* 64-A: 1053–1058, 1982.
13. Carek, PJ and Hawkins, A. Rupture of pectoralis major during parallel bar dips: Case report and review. *Med Sci Sports Exerc* 30: 335–338, 1998.
14. Centers for Disease Control and Prevention (CDC). Trends in strength training - United States, 1998–2004. *MMWR Morb Mortal Wkly Rep* 55: 769–772, 2006.
15. Cools, AM, Declercq, GA, Cambier, DC, Mahieu, NN, and Witvrouw, EE. Trapezius activity and intramuscular balance during isokinetic exercise in overhead athletes with impingement symptoms. *Scand J Med Sci Sports* 17: 25–33, 2007.
16. Cools, AM, Witvrouw, EE, Declercq, GA, Danneels, LA, and Cambier, DC. Scapular muscle recruitment patterns: Trapezius muscle latency with and without impingement symptoms. *Am J Sports Med* 31: 542–549, 2003.
17. Cools, AM, Witvrouw, EE, Mahieu, NN, and Danneels, LA. Isokinetic scapular muscle performance in overhead athletes with and without impingement symptoms. *J Athl Train* 40: 104–110, 2005.
18. Cope, MR, Ali, A, and Bayliss, NC. Biceps rupture in body builders: Three case reports of rupture of the long head of the biceps at the tendon-labrum junction. *J Shoulder Elbow Surg* 13: 580–582, 2004.
19. Cresswell, TR and Smith, RB. Bilateral anterior shoulder dislocations in bench pressing: an unusual cause. *Br J Sports Med* 32: 71–72, 1998.
20. Duchow, J, Kelm, J, and Kohn, D. Acute ulnar nerve compression syndrome in a powerlifter with triceps tendon rupture: A case report. *Int J Sports Med* 21: 308–310, 2000.
21. Esenkaya, I, Tuygun, H, and Turkmen, M. Bilateral anterior shoulder dislocation in a weight lifter. *Phys Sportsmed* 28: 1–2, 2000.
22. Fees, M, Decker, T, Snyder-Mackler, L, and Axe, MJ. Upper extremity weight-training modifications for the injured athlete. A clinical perspective. *Am J Sports Med* 26: 732–742, 1998.
23. Feigenbaum, MS and Pollock, ML. Prescription of resistance training for health and disease. *Med Sci Sports Exerc* 31: 38–45, 1999.
24. Fleck, SJ and Falkel, JE. Value of resistance training for the reduction of sports injuries. *Sports Med* 3: 61–68, 1986.
25. Garth, WP, Allman, FL, and Armstrong, WS. Occult anterior subluxations of the shoulder in noncontact sports. *Am J Sports Med* 15: 579–585, 1987.
26. Gill, I and Mbubaegbu, C. Fracture shaft of clavicle, an indirect injury from bench pressing. *Br J Sports Med* 38: e26, 2004.
27. Goertzen, M, Schoppe, K, Lange, G, and Schulitz, KP. Injuries and damage caused by excess stress in bodybuilding and power lifting. *Sportverletz Sportschaden* 3: 32–36, 1989.
28. Goeser, CD and Aikenhead, JA. Rib fracture due to bench pressing. *J Manipulative Physiol Ther* 13: 26–29, 1990.
29. Goodman, CE, Kenrich, MM, and Blum, MV. Long thoracic nerve palsy: A follow-up study. *Arch Phys Med Rehabil* 56: 352–358, 1975.
30. Gross, ML, Brenner, SL, Esformes, I, and Sonzogni, JJ. Anterior shoulder instability in weight lifters. *Am J Sports Med* 21: 599–603, 1993.
31. Haupt, HA. Upper extremity injuries associated with strength training. *Clin Sports Med* 20: 481–490, 2001.
32. Heggland, EJ and Parker, RD. Simultaneous bilateral glenoid fractures associated with glenohumeral subluxation/dislocation in a weightlifter. *Orthopedics* 20: 1180–1183, 1997.
33. Izzi, J, Dennison, D, Noerdlinger, M, Dasilva, M, and Akelman, E. Nerve injuries of the elbow, wrist, and hand in athletes. *Clin Sports Med* 20: 203–217, 2001.
34. Jobe, FW and Pink, M. Classification and treatment of shoulder dysfunction in the overhead athlete. *J Orthop Sports Phys Ther* 18: 427–432, 1993.
35. Jones, C, Christensen, C, and Young, M. Resistance training injury trends. *Phys Sportsmed* 28: 1–7, 2000.
36. Keogh, J, Hume, PA, and Pearson, S. Retrospective injury epidemiology of one hundred one competitive Oceania power lifters: The effects of age, body mass, competitive standard, and gender. *J Strength Cond Res* 20: 672–681, 2006.



37. Kibler, WB, Chandler, TJ, Uhl, T, and Maddux, RE. A musculoskeletal approach to the preparticipation physical examination. Preventing injury and improving performance. *Am J Sports Med* 17: 525–531, 1989.
38. Kolber, MJ. *Shoulder Joint and Muscle Characteristics in the Recreational Weight Training Population* [dissertation]. Fort Lauderdale, FL, 2007.
39. Kolber, MJ, Beekhuizen, K, Cheng, MS, and Hellman, M. Shoulder joint and muscle characteristics in the recreational resistance training population. *J Strength Cond Res* 23: 148–157, 2009.
40. Kolber, MJ, Beekhuizen, K, Cheng, MS, and Hellman, M. The effect of a 4-week educational intervention on shoulder joint and muscle characteristics in recreational weight-training participants: A pilot study [Abstract]. *J Orthop Sports Phys Ther* 39: OPO2213, 2009.
41. König, M and Biener, K. [Sport-specific injuries in weight lifting]. *Schweiz Z Sportmed* 38: 25–30, 1990.
42. Laudner, GK, Sipes, CR, and Wilson, TJ. The acute effects of sleeper stretches on shoulder range of motion. *J Athl Train* 43: 359–363, 2008.
43. Lestos, A, Sagantos B, Michalis D, Baschalis M, Baltopoulos P. Occult shoulder instability in weight lifters. *The 14th International Jerusalem Symposium on Sports Medicine: program and book of abstracts. Special issue: Israeli Journal of Sports Medicine*. 1998.
44. Lin, JJ, Lim, HK, and Yang, JL. Effect of shoulder tightness on glenohumeral translation, scapular kinematics, and scapulohumeral rhythm in subjects with stiff shoulders. *J Orthop Res* 24: 1044–1051, 2006.
45. Lin, JJ, Wu, YT, Wang, SF, and Chen, SY. Trapezius muscle imbalance in individuals suffering from frozen shoulder syndrome. *Clin Rheumatol* 24: 569–575, 2005.
46. Lodhia, K, Barunashish, B, and Mcgillcuddy, J. Peripheral nerve injuries in resistance training. *Phys Sportsmed* 33: 1–19, 2005.
47. Lyons, PM and Orwin, JF. Rotator cuff tendinopathy and subacromial impingement syndrome. *Med Sci Sports* 30: 12–17, 1998.
48. Macdermid, JC, Ramos, J, Drosdowech, D, Faber, K, and Patterson, S. The impact of rotator cuff pathology on isometric and isokinetic strength, function, and quality of life. *J Shoulder Elbow Surg* 13: 593–598, 2004.
49. Maffulli, N and Mikhail, HM. Bilateral anterior glenohumeral dislocation in a weight lifter. *Injury* 21: 254–256, 1990.
50. Magee, DJ. *Orthopedic Physical Assessment*. Philadelphia, PA: W.B. Saunders Company, 1987.
51. Mazur, LJ, Yetman, RJ, and Risser, WL. Weight-training injuries. Common injuries and preventative methods. *Sports Med* 16: 57–63, 1993.
52. McClure, P, Balaicuis, J, Heiland, D, Broersma, EM, Thorndike, KC, and Wood, A. A randomized controlled comparison of stretching procedures for posterior shoulder tightness. *J orthop Sports Phys Ther* 37: 108–114, 2007.
53. Mihata, T, Lee, Y, McGarry, MH, Abe, M, and Lee, TQ. Excessive humeral external rotation results in increased shoulder laxity. *Am J Sports Med* 32: 1278–1285, 2004.
54. Mohtadi, NGH. Advances in the understanding of anterior instability of the shoulder. *Clin Sports Med* 10: 863–870, 1991.
55. Mondelli, M, Cioni, R, and Federico, A. Rare mononeuropathies of the upper limb in bodybuilders. *Muscle Nerve* 21: 809–812, 1998.
56. Myers, JB, Laudner, KG, Pasquale, MR, Bradley, JP, and Lephart, SM. Glenohumeral range of motion deficits and posterior shoulder tightness in throwers with pathological internal impingement. *AJSM* 34: 1–6, 2005.
57. Neviaser, TJ. Weight lifting. Risks and injuries to the shoulder. *Clin Sports Med* 10: 615–621, 1991.
58. Petrera, JE and Trojaborg, W. Conduction studies of the long thoracic nerve in serratus anterior palsy of different etiology. *Neurology* 34: 1033–1037, 1984.
59. Powell, KE, Heath, GW, Kresnow, MJ, Sacks, JJ, and Branche, CM. Injury rates from walking, gardening, weightlifting, outdoor bicycling, and aerobics. *Med Sci Sports Exerc* 30: 1246–1249, 1998.
60. Reddy, AS, Mohr, KJ, Pink, MM, and Jobe, FW. Electromyographic analysis of the deltoid and rotator cuff muscles in persons with subacromial impingement. *J Shoulder Elbow Surg* 9: 519–523, 2000.
61. Reeves, RV, Laskowski, ER, and Smith, J. Resistance training injuries: Part 1: Diagnosing and managing acute conditions. *Phys Sportsmed* 26: 67, 1998.
62. Reeves, RV, Laskowski, ER, and Smith, J. Resistance training injuries: Part 2: Diagnosing and managing chronic conditions. *Phys Sportsmed* 26: 54, 1998.
63. Rengachary, SS, Neff, JP, Singer, PA, and Brackett, CE. Suprascapular entrapment neuropathy: A clinical, anatomical, and comparative study, part 1: Clinical study. *Neurosurgery* 5: 441–446, 1979.
64. Risser, WL. Musculoskeletal injuries caused by resistance training. Guidelines for prevention. *Clin Pediatr (Phila)* 29: 305–310, 1990.
65. Risser, WL. Weight-training injuries in children and adolescents. *Am Fam Physician* 44: 2104–2108, 1991.
66. Rossi, F, Triggs, WJ, Gonzalez, R, and Shafer, SJ. Bilateral medial pectoral neuropathy in a weight lifter. *Muscle Nerve* 22: 1597–1599, 1999.
67. Scavenius, M and Iversen, BF. Nontraumatic clavicular osteolysis in weight lifters. *Am J Sports Med* 20: 463–467, 1992.
68. Scavenius, M, Iversen, BF, and Sturup, J. Resection of the lateral end of the clavicle following osteolysis, with emphasis on non-traumatic osteolysis of the acromial end of the clavicle in athletes. *Injury* 18: 261–263, 1987.
69. Schultz, JS and Leonard, JA Jr. Long thoracic neuropathy from athletic activity. *Arch Phys Med Rehabil* 73: 87–90, 1992.
70. Sharkey, N and Marder, R. The rotator cuff opposes superior translation of the humeral head. *Am J Sports Med* 23: 270–275, 1995.
71. Shellhaas, JS, Glaser, DL, and Drezner, JA. Distal clavicular stress fracture in a female weight lifter. *Am J Sports Med* 32: 1755–1758, 2004.
72. Starkey, DB, Pollock, ML, Ishida, Y, Welsch, MA, Brechue, WF, Graves, JE, and Feigenbaum, MS. Effect of resistance training volume on strength and muscle thickness. *Med Sci Sports Exerc* 28: 1311–1320, 1996.
73. Tyler, TF, Nicholas, SJ, Roy, T, and Gleim, GW. Quantification of posterior capsule tightness and motion loss in patients with shoulder impingement. *Am J Sports Med* 28: 668–673, 2000.
74. Tyler, TF, Roy, T, Nicholas, SJ, and Gleim, GW. Reliability and validity of a new method of measuring posterior shoulder tightness. *J Orthop Sports Phys Ther* 29: 262–269; discussion 270–264, 1999.
75. Valeriote, J, Purchase, RJ, and Kelly, JD. Simultaneous bilateral pectoralis major muscle rupture. *Am J Orthop* 34: 301–302, 2005.
76. Van der Wall, H, McLaughlin, A, Bruce, W, Frater, CJ, Kannangara, S, and Murray, IP. Scintigraphic patterns of injury in amateur weight lifters. *Clin Nucl Med* 24: 915–920, 1999.
77. Warner, JJ, Micheli, LJ, Arslanian, LE, Kennedy, J, and Kennedy, R. Patterns of flexibility, laxity, and strength in normal shoulders and shoulders with instability and impingement. *Am J Sports Med* 18: 366–375, 1990.
78. Wolfe, SW, Wickiewicz, TI, and Cavanaugh, JT. Ruptures of the pectoralis major muscle: An anatomic and clinical analysis. *Am J Sports Med* 20: 587–593, 1992.
79. Yu, J and Habib, P. Common injuries related to weightlifting: MR imaging perspective. *Semin Musculoskelet Radiol* 9: 289–301, 2005.
80. Zander, D, Perlick, L, and Diedrich, O. [N. thoracicus longus lesion—a rare injury in weight lifting]. *Sportverletz Sportschaden* 14: 151–154, 2000.
81. Zeiss, J, Woldenberg, LS, Saddemi, SR, and Ebraheim, NA. MRI of suprascapular neuropathy in a weight lifter. *J Comput Assist Tomogr* 17: 303–308, 1993.
82. Zemek, MJ and Magee, DJ. Comparison of glenohumeral joint laxity in elite and recreational swimmers. *Clin J Sport Med* 6: 40–47, 1996.